

Skin Repair Properties of *d*-Limonene and Perillyl Alcohol in Murine Models

Patrizia A. d'Alessio^{1*}, Massoud Mirshahi², Jean-François Bisson³ and Marie C. Béné⁴

¹University Paris Sud-11 Biopark Campus Cancer, Villejuif, France; ²University Paris 6-Pierre et Marie Curie, Inserm E 9912, Paris, France; ³ETAP Research Centre, Vandoeuvre-lès-Nancy, France; ⁴Hematology, CHU & Nantes University, Nantes, France

Abstract: The orange-peel derived terpene *d*-Limonene, probably through its metabolite, perillyl alcohol (POH), has been reported to have tissue-repair properties. Two murine models of respectively 12-O-Tetradecanoylphorbol-13-Acetate (TPA)-induced dermatitis and mechanical skin lesion were used here to assess the efficacy of *d*-Limonene or POH applied topically. Macroscopic and microscopic evaluation of skin lesions was performed as well as that of P-selectin expression, together with measurements of serum concentrations of IL-1 β , IL-6 and TNF- α in the first model. Healing and angiogenesis around the scar were examined in the second model. Because differences in angiogenesis were noted, the effect of both *d*-Limonene and POH was further tested on an *in vitro* model of endothelial microtubules formation. Both *d*-Limonene and POH reduced the severity and extension of TPA-induced skin lesions with significantly lowered macroscopic and microscopic scores ($p < 0.04$ in both cases). Moreover, the expression of P-selectin induced by TPA was abrogated by POH and significantly lower serum concentrations of IL-6 and TNF- α were observed in *d*-Limonene- and POH-treated mice ($p < 0.04$ and 0.03). In the second model, tissue regeneration was improved, especially by POH, and was clearly associated with reduced neovascularization. This surprising anti-angiogenic effect was confirmed in the matrigel model of endothelial microtubules formation. These studies show that *d*-Limonene and POH demonstrate significant anti-inflammatory effects in murine dermal inflammation and wound-healing. The decreased systemic cytokine production as well as a consistent inhibition of endothelial P-selectin expression and neo-vascularization induced by these terpenic compounds contribute to their healing effects on the epidermal barrier.

Keywords: Angiogenesis inhibition, *d*-Limonene, inflammation inhibition, P-selectin, wound healing.

INTRODUCTION

Epithelial barriers are major determinants of first line defense in innate immunity, preserving the integrity of environmental interfaces. These barriers include mucosal areas as well as the most exposed skin envelope. In the epidermis and dermis, numerous fine-tuned mechanisms allow to exclude pathogens and irritants while containing inflammation. When these naturally active protections are overwhelmed (i.e. infections, wounds), a rapid sequence of events aims at restoring integrity. It may however be necessary, in some instances, to help these natural phenomena to achieve return to homeostasis, for instance in chronic inflammation or wounds. This can be performed by resorting to pharmacological compounds or natural substances. To this avail, monoterpenes extracted from essential oils have proven to be useful to control inflammation [1], and thymol was recently shown to accelerate wound healing [2].

d-Limonene, the prototype of monoterpenes [3] has long been known to inhibit tumor growth [4] by several cellular mechanisms [5, 6]. One of them is the inhibition of angiogenesis [7], which could also help to reduce inflammation.

Our group has previously been involved in identifying more thoroughly the beneficial properties of monoterpenes in inflammation control [8, 9] and tissue repair [10]. It was further shown that terpenes from essential oils are, in particular, indeed active on tumor necrosis alpha (TNF α)- or interleukin-6 (IL-6)-mediated inflammation [9, 11, 12].

In order to confirm that *d*-Limonene and its metabolite perillyl alcohol (POH) could participate in helping the return to skin homeostasis and integrity *in vivo*, we used two experimental murine models of respectively skin inflammation and wound healing.

TPA-induced dermatitis was generated as reported elsewhere [13] and treated by skin application of *d*-Limonene and POH. Similarly, epidermal incisions were submitted to *d*-Limonene and POH treatment. Moreover, the influence of *d*-Limonene and POH on neoangiogenesis was studied *in vitro* on human umbilical cord endothelial cells.

MATERIALS AND METHODS

Drugs

d-Limonene (C₁₀H₁₆, CAS Number 5989-54-8, 97% purity) and perillyl alcohol (POH, C₁₀H₁₆O, CAS Number 18457-55-1, 98% purity) were purchased from SIGMA-ALDRICH (Saint-Quentin Fallavier, France) and prepared

*Address correspondence to this author at the Biopark Campus Cancer, 1, mail Pr Georges Mathé, 94807 Villejuif – France; Tel: 33-6-87 47 80 32; E-mails: patrizia.d-alessio@inserm.fr, endocell@wanadoo.fr

each day as a fresh solution by dissolution in sunflower oil as vehicle, according to AISA Therapeutics recommendations.

TPA (12-O-Tetradecanoylphorbol-13-acetate, C₃₆H₅₈O₆, CAS Number 16561-29-8, 98% purity) was purchased from Fluka (France) as a film and reconstituted in acetone.

Animals

Twenty-four Hairless Skh-1 (CrI:SKH-1-hr) female mice (20–25 g) were obtained from Charles River (Charles River Breeding Centre, L'Arbresle, France). At reception, the mice were labeled and maintained in the standardized conditions of an animal house with a 24±2°C temperature and 50±10% hygrometry. Food and water were provided *ad libitum*. The animal house had an inverted light/dark cycle of 12 hours with lights on from 21:00 to 09:00. Mice were allowed a one-week adaptation period to the laboratory conditions.

Supervision and animal weighting were performed daily. This supervision also allowed the segregation of weak or moribund animals following principles and guidelines of ASAB [14], Canadian Council for Animal Protection [15] and UK legislation of *in vivo* aspects in inflammation research [16]. The protocol used for this study as all the SOAPS in use at ETAP was approved by the Director's Office of Veterinary Services and the local Committee on the Ethics of Animal Experiments in Nancy, and authorized by the French government (Governmental authorization no. A 54-547-1). All efforts were made to minimize suffering. Autopsies were itemized, and pathological modifications were identified and recorded. Each organ presenting macroscopic modifications was processed in view of further histological analysis.

Induction of Skin Inflammation

Skin inflammation was induced by daily cutaneous application on the backs of all mice except the control group, during 7 consecutive days, of the acetic solution of TPA (asTPA). To this purpose, animals were restrained in an adapted device featuring a skin exposure aperture over which 100 µL of asTPA (corresponding to 20 µg of TPA) were applied. As soon as the as TPA was evaporated, mice were removed for the restraining device and replaced in their cages.

Study of Skin Anti-inflammatory Effects of *d*-Limonene and POH

The twenty-four animals were allocated to four experimental groups (n=6 in each group): group i was a negative control group without skin inflammation and daily cutaneous treatment with sunflower oil only (vehicle), group ii (TPA) had TPA-induced skin inflammation (positive control), group iii (*d*-Lim 10) had TPA-induced skin inflammation and treatment with 10 mg/kg of *d*-Limonene and group iv (POH 10) had TPA-induced skin inflammation and treatment with 10 mg/kg of POH. The dose was derived from previous experiments from our group [17].

For groups iii and iv, freshly prepared solutions of *d*-Limonene or POH in sunflower oil were applied cutaneously on a daily basis on the whole back of each animal, three days before (pre-treatment) and during the seven days of TPA-induction of skin inflammation.

Cytokine Profiles

Blood samples were taken from each mouse 4 hours after the last cutaneous treatment. About 0.5 mL of blood was collected by cardiac puncture in a dry tube (Terumo, Leuven, Belgium), stored at +4°C for 30 minutes and then centrifuged at 1500g for 15 minutes. Serum was aliquoted in polypropylene tubes, frozen at -20°C and stored at -80°C before cytokine analyses. After thawing of all the serum samples, the three pro-inflammatory cytokines, IL-1β, IL-6 and TNF-α were assayed simultaneously with Bio-Rad mouse 3-Plex A panel kits by using the Bio-Plex technique (Bio-Rad, Marnes-la-Coquette, France). Assays were performed in duplicate.

Skin Macroscopic Scoring

Mice were observed blindly by two different persons unaware of the treatments given. The area and degree of dorsal cutaneous inflammation were assessed in order to calculate a global macroscopic score of cutaneous inflammation. A macroscopic score between 0 and 12 was attributed to all skins. Score 0 meant no skin inflammation. Skin inflammation was scored between 1 and 3 when weak, 4 and 6 when medium, 7 and 9 when significant and 10 and 12 when severe. Skin specimens were sampled, fixed and stored in preservative (Roti[®]-Histofix 4%, Carl Roth, Karlsruhe, Germany) for histo-pathological analysis with classical pathological methods after paraffin embedding.

Skin Microscopic Scoring

Histopathological analysis was carried out blindly on 10 sections (5µm thickness) from each skin specimen (by Dr. P. Roignot, Director of the Pathology Centre of Dijon, France). The degree of inflammation was characterized by several parameters for epidermis, dermis and hypodermis in order to define a global microscopic score of cutaneous inflammation. A score of 0 corresponded to a normal skin without any inflammatory infiltrate or structural modification in the different layers. Scores between 1 and 8 indicated weak skin inflammation, 9 and 16 medium skin inflammation, 17 and 24 important skin inflammation and 25 and 32 very important skin inflammation.

P-selectin Expression

For the analysis of P-selectin expression in blood vessels, two 5µm thick sections of each skin sample were prepared and treated during 30 minutes with CC1 buffer (Ventana Medical Systems, AZ). One of the two sections was incubated during 30 minutes with anti-P-selectin monoclonal antibody (Acris, Harford, Germany) at a dilution of 1/200 before blocking endogenous peroxidase activity with 0.1% hydrogen peroxidase. Both sections were then incubated with a peroxidase-conjugated anti-IgG1 polyclonal antibody (Acris) for 30 minutes and washed with phosphate buffer saline, after which slides were visualized by 3,3'-diaminobenzidine tetrahydrochloride Ventana iVIEW detection kit (Ventana Medical Systems). The observation of P-selectin staining on the slides was performed blindly by Dr. P. Roignot (Pathology Centre of Dijon, France).

Study of Wound Healing Effects of *d*-Limonene and POH

For the analysis of skin repair, mice were anesthetized with a mixture of ketamine/xylazine (2/3-1/3 v/v) diluted 5 times in saline (NaCl 0.9%). One centimeter dorsal incisions were made on each flank of the mouse through the epidermis, dermis and subcutaneous tissue, leaving the deep fascia intact.

Eight animals were allocated to four experimental groups (n=2 in each group): group i (control) without skin incisions and daily cutaneous treatment with sunflower oil, group ii (incision) with skin incisions and treatment with sunflower oil, group iii (*d*-Lim 10) with skin incisions and treatment with 10 mg/kg of *d*-Limonene and group iv (POH) with skin incisions and treatment with 10 mg/kg of POH. For groups iii and iv, freshly prepared solutions of *d*-Limonene or POH were applied topically to the wounds with a bristle brush on a daily basis, one hour before (pre-treatment) and then eight days after skin wounding.

Wound Healing Process

Daily observation of the wound was performed. Twenty-four hours after the last topical treatment of vehicle, *d*-Limonene or POH, i.e. nine days after the wounding, animals were sacrificed by an overdose of pentobarbital. The dorsal pelt containing the healing scars was photographed and removed for external and internal observation of skin samples.

In vitro Matrix Neoangiogenesis

The technique of Kern *et al.* [18] was adapted as follows: 1.5×10^5 human microvasculature endothelial cells (HMEC) and human bone marrow endothelial cells (HBMEC) were cultured in 24 multiwell plates filled with M131 containing 5% fetal calf serum (FCS), 100 IU/mL penicillin, 100 μ g/mL streptomycin and 5% microvascular growth supplement (MVGS). After 18 hours at 37°C, 5% CO₂ in air, the cells were carefully washed twice with RPMI and detached with a non-enzymatic solution containing acutase (PAA, France). The effect of *d*-Limonene and POH on capillary formation was analyzed on low matrigel base in a medium devoid of growth factor. To this end, 96-well plates pre-coated with matrigel (Becton-Dickinson, Le Pont de Claix, France) were used and matrigel was allowed to polymerize for 1-2 hours at 37°C. Thereafter, 3.5×10^4 cells/well, in M131, without either FCS or MVGS, were seeded onto the matrigel-coated wells in presence of various concentrations and of *d*-Limonene and POH. Following different incubation periods at 37°C, capillary tube formation was assessed using an inverted microscope fitted with a digital camera (Nikon-Diaphot, Nikon, Tokyo, Japan). The capillary network was quantitated by recording the number and length of connections between three or more capillary-like structures/field with the aid of the Archimed program developed by Microvision (Paris, France).

Statistical Analyses

All data are presented as mean \pm SEM. Statistical analyses were carried out using the *Statview 5* statistical package (SAS, Institute Inc., USA). Non-parametric tests were applied: one-way ANOVA with Kruskal-Wallis test followed,

when significant, by the Mann-Whitney U-test to compare the different study variables (body weight, cytokine serum levels, macroscopic and microscopic inflammation scores) between the various groups compared to controls in group i. For all comparisons, differences were considered to be significant at the level of $P < 0.05$.

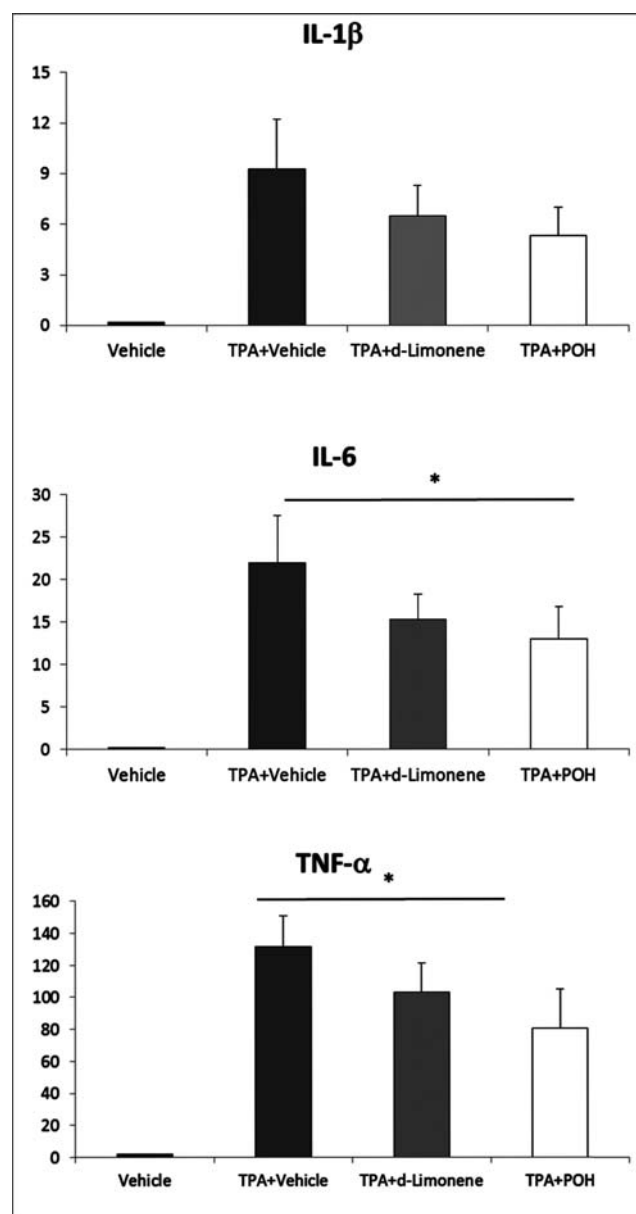


Fig. (1). Mean serum levels of cytokines (TNF- α , IL-6, IL-1 β) in treated animals at the end of the experiment. No cytokine was detected in animals who received only vehicle. Peripheral levels were maximal for animals treated with TPA and vehicle (dark gray), intermediate for those who received TPA and *d*-Limonene (light gray) and minimal for those given TPA and POH (white). Data are expressed as mean + SEM.

RESULTS

Body Weight in the TPA Model

No statistical difference was observed between the mean body weight of mice of the four treatment groups on day 1, before the initiation of topical applications, nor on days 2 or 10, respectively after three days of topical applications before induction of skin inflammation, nor 24 hours after the last treatment. A trend was observed for mean body weight decrease in treatment groups ii-iv between d2 and d10.

Cytokine Profiles in the TPA Model (Fig. 1)

When compared to control mice (0.0 ± 0.0 pg/mL in all cases), serum levels of IL-1 β , IL-6 and TNF- α were significantly increased on day 10 in all TPA-treated animals (groups i-iv).

For IL-1 β , POH resulted in the lowest serum levels increase (5.3 ± 1.7 pg/mL) while TPA-treated animals (group ii) had the highest increase (9.3 ± 2.9 pg/mL), *d*-Limonene-treated animals displaying intermediate levels (group iii, 6.5 ± 1.8 pg/mL). None of the differences were significant between these three groups.

By contrast, IL-6 levels remained significantly lower in POH-treated animals (group iv, 13.0 ± 3.8 pg/mL) compared to group ii (TPA, 22.0 ± 5.5 pg/mL, $p=0.04$) while the inter-

mediate levels observed in group iii (*d*-Limonene, 15.3 ± 3.0 pg/mL) did not significantly differ to those observed in group ii ($p=0.08$).

Similarly, TNF- α levels were significantly lower in group iv (POH, 80.6 ± 24.7 pg/mL) compared to group ii (TPA, 131.9 ± 18.9 pg/mL, $p=0.03$), while group iii animals (*d*-Limonene) had intermediate non statistically significant different levels (103.2 ± 18.0 pg/mL $p=0.08$).

Skin Macroscopic Scoring in the TPA Model

The macroscopic appearance of mice skin was clearly different and altered for TPA alone (group ii) mice (Fig. 2). Control mice (group i) had as expected a 0.0 ± 0.0 macroscopic score of skin inflammation. POH resulted in significantly lower macroscopic scores of skin inflammation (5.0 ± 0.3) than in group ii (TPA, 9.8 ± 0.6) ($p=0.002$). *d*-Limonene also resulted in significantly lower macroscopic scores of skin inflammation compared to group ii ($p=0.003$).

Histological Observation of Skin Samples and Microscopic Scoring in the TPA Model

In control group i, normal skin architecture was observed with no inflammation. In TPA-treated mice (group ii), skin specimen were highly inflammatory with often pronounced leukocyte infiltrates. In *d*-Limonene group iii, samples were

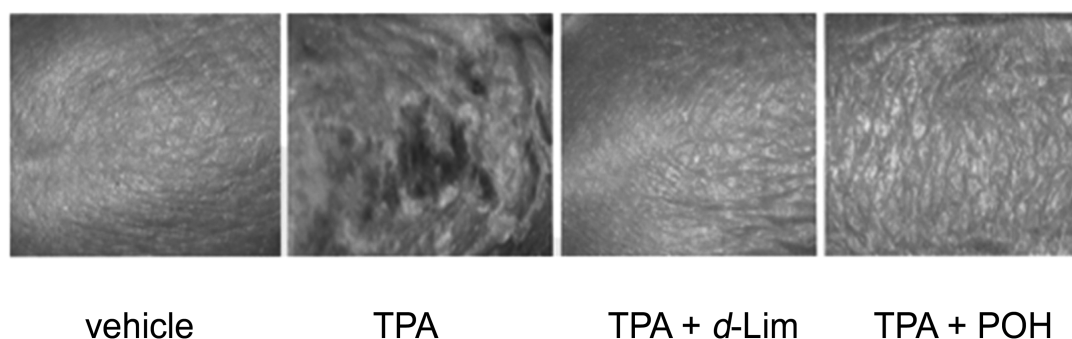


Fig. (2). Macroscopic aspect of mouse skin. Normal aspect of mouse skin after only vehicle application (left). Severe desquamation and necrosis after TPA treatment (middle left). Improved near normal aspect of TPA treated mice after application of *d*-Limonene (TPA + *d*-Lim, middle right) or POH (TPA + POH, right).

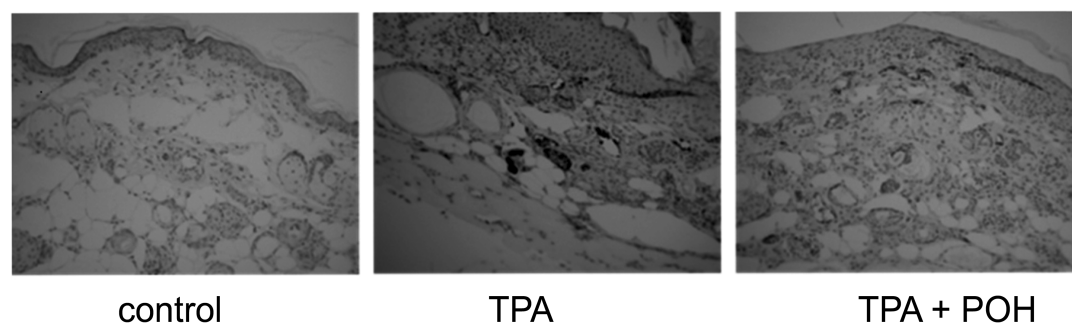


Fig. (3). P-selectin expression in immunohistochemistry on skin biopsies in the TPA model. Microscopic sections of skin samples immunostained for P-selectin and counterstained. No P-selectin expression was visible on dermal blood vessels in control, untreated animals (vehicle, left). A significant expression of P-selectin is clearly visible on most dermal blood vessels (dark brown staining) in TPA-stimulated positive controls (TPA, middle). This staining is significantly reduced after TPA stimulation followed by perillyl alcohol (TPA+POH, right) application. Initial magnification $\times 40$.

only mildly inflamed with moderate cell infiltrates. In POH group iv, very little inflammation was seen with scarce cell infiltrates.

When compared to control mice (mean score 1.3 ± 1.3), microscopic scores of skin inflammation were increased on day 10 in treated animals. Both POH (group iv, 13.3 ± 3.3) and *d*-Limonene (group iii, 16.0 ± 2.7) resulted in significantly lower microscopic scores of skin inflammation (respectively $p=0.01$ and $p=0.04$) compared to group ii (TPA, 20.8 ± 2.6).

P-selectin Expression in the TPA Model (Fig. 3)

Immunohistochemical analysis of P-selectin expression in blood vessels showed differences between the four treatment groups. In control group i, mild and heterogeneous labeling of the membrane of endothelial cells of some scattered blood vessels was observed. In mice with TPA-induced skin inflammation (group ii) and in group iii (*d*-Limonene), strong and homogeneous labeling of endothelial cells was observed. In POH group iv, mild and homogeneous labeling of endothelial cells of some scattered vessels was observed.

Wound Healing Model (Fig. 4)

Daily topical application of POH in wounded skins of hairless mice improved the healing process better than vehicle, as did also *d*-Limonene, yet less importantly. POH treatment led to a faster and better wound closure. As shown in Fig. 4 showing the inner side of skin flaps sampled at wounded areas, the amount of newly formed blood vessels was high for control mice and strikingly low for animals treated with either *d*-Limonene or POH.

In vitro Neo-angiogenesis Inhibition by *d*-Limonene (Fig. 5)

Neoangiogenesis, objectived as microtubules formation upon *in vitro* culture of endothelial cells, was already apparent in control wells at 2 hours and clearly developed at 6 hours. Similar microvasculature formation was observed in the presence of 62.6 mg/mL of POH or *d*-Limonene at 2 hours. Conversely, no microtubule formation was seen at both time points in the presence of POH at 125 and 250 mg/mL or *d*-Limonene at 250 mg/mL and a decreased number of connections was present with *d*-Limonene at 125 mg/mL. Similar but less obvious features were observed at 6 hours, where only 250 mg/mL POH still completely inhibiting microtubules formation (data not shown).

DISCUSSION

This study documents anti-inflammatory, wound-healing and anti-angiogenic properties of *d*-Limonene and its major metabolite POH, in two *in vivo* models of respectively TPA-induced inflammation or tissue repair after skin scarification, as well as in vascular microtubules generation *in vitro* on matrigel. POH appeared to be more efficient than *d*-Limonene for these effects, confirming that this metabolite is the active compound of the terpene for tissue repair [3,5].

The model of TPA-induced inflammation is commonly used for studies related to such cutaneous diseases as atopic dermatitis or psoriasis [13]. The latter remain a clinical and

therapeutic challenge. Steroids, and more recently therapeutic monoclonal antibodies have been proposed [19], allowing for a successful management, but at the price of numerous side-effects. Natural compounds, mostly of vegetal origin, have also shown some promising properties that could be further explored. Since *d*-Limonene previously showed a positive effect on intestinal inflammation and strengthening of the enterocytes epithelial barrier [17], we designed a complementary study addressing another barrier, i.e. skin.

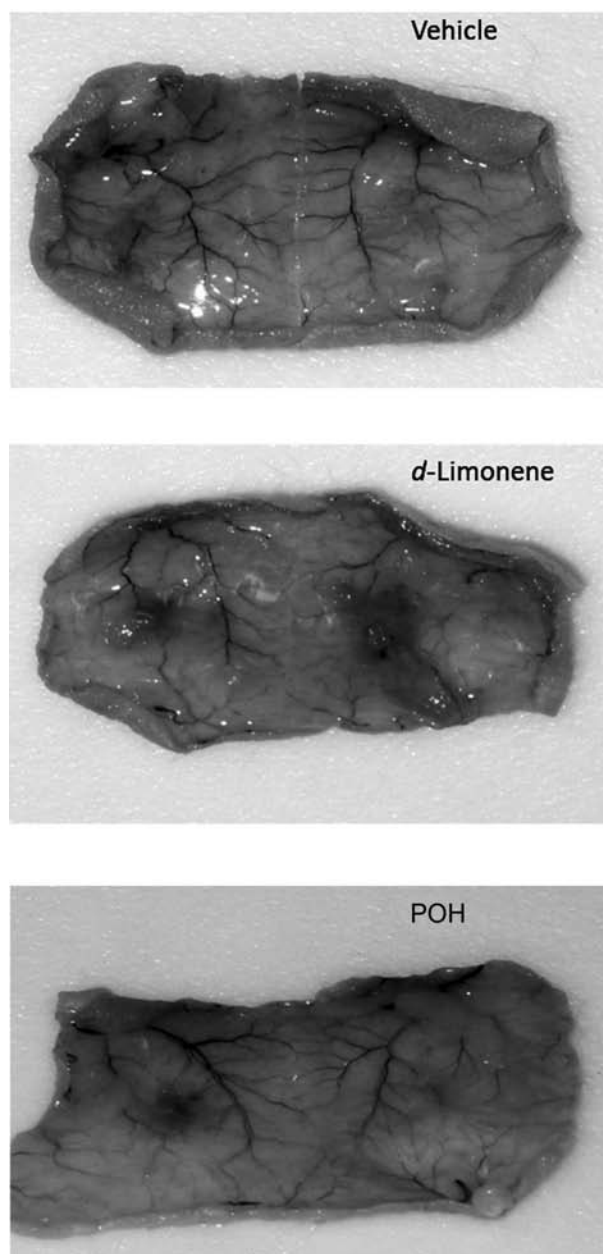


Fig. (4). Neoangiogenesis inhibition after skin incision. These figures show the bottom layer of the scarred skin after biopsy of the sacrificed animals. Control scarified mice treated with only vehicle showed good healing associated with abundant neovascularization. Conversely, animals treated with *d*-Limonene or POH that healed comparatively, show significantly less neovascularization.

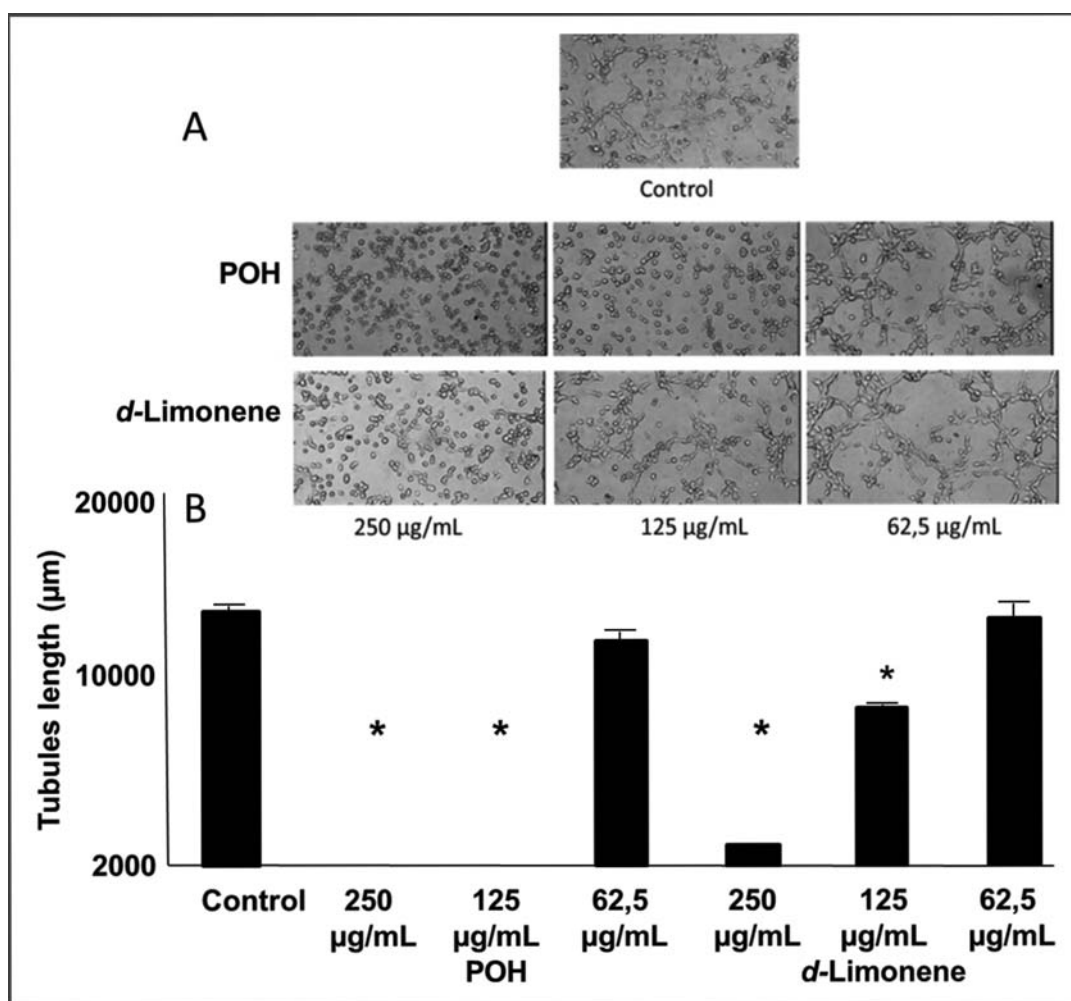


Fig. (5). Inhibition of microtubules formation on matrigel. These images were taken after 2 hours culture on Matrigel as described in Materials and Methods. The top cartoon shows spontaneous neovascularization. The middle panel shows strong inhibition of tubule formation by POH at 125 and 250 mg/mL. The bottom panel displays the slightly lesser effect of *d*-Limonene, only inhibiting microtubule formation at the highest dosage. Statistically significant tubules growth differences were measured as shown in the bottom panel (* $p < 0.001$).

Literature data on the effects of monoterpenes *d*-Limonene and geraniol [20] predominantly focus on their anti-cancer activities, justified by their capacity to inhibit protein isoprenylation [5]. The latter is a fundamental step prerequisite to the expression of adhesion molecules in vascular endothelium [5]. Geraniol and *d*-Limonene could therefore modulate the generation of inflammatory infiltrates by decreasing the expression of such molecules, as shown here for P-selectin. In keeping with this observation, P-selectin has been shown to be inducible on murine endothelial cells by TNF- α [21]. Hung and coworkers [22] similarly reported in an *in vitro* model that lycopene, a tetraterpene, is able to inhibit TNF- α induced ICAM-1 mRNA and protein expression. Monoterpenes may therefore have a protective effect on microvascular inflammatory processes [10, 23, 24], as demonstrated by the long-known pharmacological effects of geraniol [20]. Indeed the latter was identified as capable of inhibiting TNF- α -induced leukocyte adhesion [11].

Besides decreasing the expression of adhesion molecules on endothelial cells, terpenes can also act directly on angio-

genesis. This was demonstrated in the second *in vivo* murine model of skin scarification that we report here where wound healing in control animals involved sustained neoangiogenesis [25]. Intriguingly, the beneficial effect of *d*-Limonene and POH in our model was associated with a lack of neoangiogenesis, suggesting that *d*-Limonene and POH could have both intrinsic wound-healing capacities and anti-angiogenic properties. This is consistent with the matrigel *in vitro* experiments which clearly demonstrated the dose-dependent inhibition of endothelial tubules formation in the presence of *d*-Limonene and even more strikingly POH. These data are consistent with a recent publication by Murthy *et al.* also showing the antiangiogenic activity of *d*-Limonene from blood oranges on microtubules formation through *in vivo* inhibition of VEGF production [26].

CONCLUSIONS

The data reported here indicate that topical administration of *d*-Limonene has positive effects on wound healing, most likely mediated by its major metabolite POH. Intriguingly,

ingly, these benefits involve the specific capacity of POH to decrease both inflammation and neoangiogenesis. This suggests that the wound-healing properties of terpenes could involve a direct effect on epithelial cells.

CONFLICT OF INTEREST

The authors confirm that this article content has no conflicts of interest.

ACKNOWLEDGEMENTS

We would like to thank Dr. Patrick Roignot from the Pathology Centre in Dijon (France) for performing the P-selectin measurements in skin specimens. This study was funded by a grant from the French Ministry of Research to PDA "Award 2005 for innovative research".

ABBREVIATIONS

FCS	=	Fetal calf serum
HBMEC	=	Human bone marrow endothelial cells
HMEC	=	Human microvasculature endothelial cells
IL	=	Interleukin
MVGS	=	Microvascular growth supplement
POH	=	Perillyl alcohol
RPMI	=	Rosswell Park Memorial Institute
SEM	=	Standard error of the mean
TNF	=	Tumor necrosis factor
TPA	=	12-O-Tetradecanoylphorbol-13-Acetate

REFERENCES

- Millan, J.; Ridley, A.J. Rho GTPases and leucocyte-induced endothelial remodeling. *Biochem. J.*, **2005**, *385*, 329-337.
- Burridge, K.; Wenneberg, K. Rho and Rac take center stage. *Cell*, **2004**, *116*, 167-179.
- Crowell, P.L. Prevention and therapy of cancer by dietary monoterpenes. *J. Nutr.*, **1999**, *129*, 775S-778S.
- Miller, J.A.; Thompson, P.A.; Hakim, I.A.; Sherry Chow, H.H.; Thomson, C.A. *d*-Limonene: A bioactive food component from citrus and evidence for a potential role in breast cancer prevention and treatment. *Oncol. Rev.*, **2011**, *5*, 31-42.
- Crowell, P.L.; Lin, S.; Vedejs, E.; Gould, M.N. Identification of metabolites of the anti-tumor agent *d*-Limonene capable of inhibiting protein isoprenylation and cell growth. *Cancer Chemother. Pharmacol.*, **1992**, *31*, 205-212.
- Hardcastle, I.R.; Rowlands, M.G.; Barber, A.M.; Grimshaw, R.M.; Mohan, M.K.; Nutley, B.P.; Jarman, M. Inhibition of protein prenylation by metabolites of *d*-Limonene. *Biochem. Pharmacol.*, **1999**, *57*, 801-809.
- Loutrari, H.; Magkouta, S.; Pyriochou, A.; Koika, V.; Kolisis, F.N.; Papapetropoulos, A.; Roussos, C. Mastic oil from *Pistacia lentiscus* var. *chia* inhibits growth and survival of human K562 leukemia cells and attenuates angiogenesis. *Nutr. Cancer*, **2006**, *55*, 86-93.
- Bisson, J.F.; Menut, C.; d'Alessio, P.A. Anti-inflammatory senescence activates 5203-L molecule to promote healthy aging and prolongation of lifespan. *Rejuven. Res.*, **2008**, *11*, 399-407.
- d'Alessio, P.A.; Ostan, R.; Valentini, L.; Bourdel-Marchasson, I.; Pinto, A.; Buccolini, F.; Franceschi, C.; Béné, M.C. Gender differences in response to dietary supplementation by Orange Peel Extract in elderly people in the Ristomed study: Impact on Quality of Life and inflammation. *Prime*, **2012**, *2*, 30-37.
- d'Alessio, P.A. Use of a monoterpene to increase tissue repair (PCT WO 2009/040420).
- Abe, S.; Maruyama, N.; Hayama, K.; Ishibashi, H.; Inoue, S.; Oshima, H.; Yamaguchi, H. Suppression of tumor necrosis factor- α -induced neutrophil adherence responses by essential oils. *Med. Inflammation*, **2003**, *12*, 323-328.
- Brito, R.G.; Guimaraes, A.G.; Quintans, J.S.; Santos, M.R.; De Sousa, D.P.; Badaue-Passos, D. Jr; de Lucca, W. Jr; Brito, F.A.; Barreto, E.O.; Oliveira, A.P.; Quintans, L.G. Jr. Citronellol. A monoterpene alcohol, reduces nociceptive and inflammatory activities in rodents. *J. Nat. Med.*, **2012**, *66*, 637-644.
- Medeiros, R.; Otuki, M.F.; Avellar, M.C.; Calixto, J.B. Mechanisms underlying the inhibitory actions of the pentacyclic triterpene alpha-amyrin in the mouse skin inflammation induced by phorbol ester 12-O-tetradecanoylphorbol-13-acetate. *Eur. J. Pharmacol.*, **2007**, *559*, 227-235.
- ASAB Ethical Committee. Guidelines for the treatment of animals in behavioral research and teaching. *J. Anim. Behav.*, **2006**, *71*, 245-253.
- Canadian Council on Animal Care. Guide to the care and use of experimental animals. Ed.; E.D. Olfert DVM, Cross BM and McWilliam DVM., **2003**.
- Brain, S. UK legislation of *in vivo* aspects in inflammation research. In: *In vivo* models of inflammation, Ed; Stevenson CS, Marshall LA and Morgan DW, CA. **2006**.
- d'Alessio, P.A.; Ostan, R.; Bisson, J.F.; Schulzke, J.D.; Ursini, M.V.; Béné, M.C. Oral administration of *d*-Limonene controls inflammation in rat colitis and displays anti-inflammatory properties as diet supplementation in humans. *Life Sci.*, **2013**, *92*, 1151-1156.
- Kern, P.A.; Knedler, A.; Eckel, R.H. Isolation and culture of microvascular endothelium from human adipose tissue. *J. Clin. Invest.*, **1983**, *71*, 1822-1829.
- Mossner, R.; Reich, K. Management of severe psoriasis with TNF antagonists. Adalimumab, etanercept and infliximab. *Curr. Probl. Dermatol.*, **2009**, *38*, 107-136.
- Yamawaki, T. Pharmacological effects of geraniol. *Nippon Yakurigaku Zasshi*, **1962**, *58*, 394-400.
- Liu, Z.; Miner, J.J.; Yago, T.; Yao, L.; Lupu, F.; Xia, L.; McEver, R.P. Differential regulation of human and murine P-selectin expression and function *in vivo*. *J. Exp. Med.*, **2010**, *207*, 2975-2987.
- Hung, C.F.; Huang, T.F.; Chen, B.H.; Shieh, J.M.; Wu, P.H.; Wu, W.B. Lycopene inhibits TNF α -induced endothelial ICAM-1 expression and monocyte-endothelial adhesion. *Eur. J. Pharmacol.*, **2008**, *586*, 275-282.
- d'Alessio, P.A. Endothelium as pharmacological target. *Curr. Op. Invest. Drugs*, **2002**, *2*, 1720-1724.
- d'Alessio, P.A. Aging and the endothelium. *J. Exp. Gerontol.*, **2004**, *39*, 165-171.
- Mills, S.J.; Ashworth, J.J.; Gilliver, S.C.; Hardman, M.J.; Ashcroft, G.S. The sex-steroid precursor DHEA accelerates cutaneous wound healing via the estrogen receptor. *J. Invest. Dermatol.*, **2005**, *125*, 1053-1062.
- Chidambara Murthy, K.N.; Jayaprakasha, G.K.; Patil, B.S. *d*-Limonene rich volatile oil from blood oranges inhibits angiogenesis, metastasis and cell death in human colon cancer cells. *Life Sci.*, **2012**, *91*, 429-439.